

# Prosthetic and Surgical Management of Atypical Space When Teeth Are Missing

Sergio Rubinstein, DDS; Barry P. Levin, DMD; Alexandra Fulreader, DDS; David Barack, DDS; and Toshiyuki Fujiki, RDT

**Abstract:** When a patient presents with congenitally missing teeth, early diagnosis and comprehensive treatment planning are critical to effective restorative management. Interdental space allocation must be identified to accommodate proper clinical crown proportion(s) through a surgical-prosthetic solution. This article, which presents two case reports describing situations that clinicians may commonly face, demonstrates the management of atypical tooth spacing caused by congenitally missing teeth. The implementation of interdisciplinary therapy resulted in successful outcomes from both functional and esthetic perspectives.

The presentation of patients with congenitally missing teeth is not an uncommon occurrence. In such cases orthodontic, periodontal, and restorative management can have a dramatic, lifelong impact on the patient. Functional and cosmetic outcomes both may depend on early diagnosis and comprehensive treatment planning. If this condition is not diagnosed at a relatively young age, the treatment implications could adversely affect esthetics, periodontal health, and function long-term. The American Association of Orthodontics recommends such referral be made when the patient is around 7 years of age.<sup>1</sup> The later the problem is identified, the more complex the management of the problem will likely become and the greater the chance of compromised outcomes resulting.

It is critical to identify interdental space allocation to accommodate proper clinical crown proportion(s) through a surgical-prosthetic solution. Advanced prosthetic planning can result in ideal final restoration(s) with sound hard- and soft-tissue foundations. This approach is conducive to yielding not only a cosmetic solution but also a physiologically healthy and stable outcome.

When congenitally missing teeth are diagnosed at an early age, proper treatment planning may be implemented, starting with the pediatric dentist and orthodontist. Both parties are instrumental in preoperative planning, even though they typically will not be involved in the final treatment. Besides planning the replacement of the congenitally missing teeth, the preoperative plan also should identify possible existing or future airway problems that could alter the timing and method of the implementation of orthodontic treatment. Sleep apnea diagnosis at an early age can affect the space allocation for the replacement of missing teeth.<sup>2</sup>

If interdisciplinary treatment is not applied at an early age, the surgeon and restorative dentist often may eventually be confronted with a less-than-ideal situation. Even when interdisciplinary treatment is established from the outset, compromises in some cases still may be inevitable. Various circumstances and dental conditions can interfere with optimal outcomes. These include adolescent growth, jaw discrepancies, occlusion issues, temporomandibular disorders, teeth abnormalities, periodontal problems (osseous and soft tissues), and missing teeth.

The purpose of this article is to demonstrate the management of atypical spaces caused by congenitally missing teeth. In the clinical examples presented, interdisciplinary therapy involving multiple specialists resulted in successful outcomes from both functional and esthetic perspectives. These cases demonstrate common situations dental practitioners face and their successful management.

## Case 1

A 20-year-old female patient presented with fused primary lower central incisors and congenitally missing permanent central incisors (Figure 1 and Figure 2). With the treatment plan including extraction of the deciduous incisors, the mesial-distal space was less than ideal to develop an acceptable cosmetic result, especially because the teeth to be replaced were in the esthetic zone. Despite the need to replace two mandibular incisors, the placement of two implants was not a feasible option due to the tight proximity between the teeth to be replaced and the adjacent natural teeth.<sup>3,4</sup>

Long-term stability is paramount and excellent bone preservation circumferentially around implants is necessary to enhance the predictability of favorable tissue response.<sup>5,6</sup> Furthermore, the

treatment plan must allow for healthy peri-implant bone and soft tissue to materialize, especially if implants are to be placed,<sup>7</sup> and this maturation should occur prior to delivery of the final restoration. Other factors, such as implant positioning<sup>8</sup> and mucosal thickness,<sup>7,9</sup> can also play key roles in achieving postoperative soft-tissue thickness, peri-implant bone levels, and esthetic stability.

With suboptimal interdental space available, orthodontic treatment was planned to minimize the possibility of a cosmetic compromise. Orthodontic treatment for a young adult differs from that of a child because further growth of the patient will be minimal compared to the growth of a child. While esthetic demands usually are high with an adult patient, the establishment of the best possible occlusal scheme, including canine rise, is also critical. If accomplished, the proper management of poor interdental spacing issues can help protect the health of the future implant and crown. In this case interproximal stripping was implemented during orthodontic treatment to gain proper space for implant placement and the restoration while maximizing esthetics during the orthodontic treatment (Figure 3).<sup>10</sup>

Occasionally, clinical outcomes are impacted by the patient's preferences and circumstances, such as limited time to complete treatment and a desire to obtain the final restoration faster than what may be ideal for a given treatment approach. In this case the

patient was a medical school student who was unable to complete protracted orthodontic treatment and whose objective was to improve esthetics with a stable solution. While the clinician would have preferred additional orthodontic therapy to provide optimal space for implant therapy to better coincide with restorative ideals, altering the patient's occlusion was never the intention, and her goals were successfully completed within her parameters.

A 3-mm x 13-mm implant (OsseoSpeed® EV, Dentsply Sirona, dentsplysirona.com) was placed as originally treatment planned, with the screw access as close as possible to the cingulum, away from the incisal edge and with proper "running room" to create the desired emergence profile (Figure 4 and Figure 5). The greatest concerns for this case were placement of the implant in a position that would allow for single-tooth replacement and preservation of the surrounding tissue architecture. For this procedure, removal of the deciduous teeth was accomplished with minimal force and with preservation of the thin facial plate. The close proximity of these roots and short inter-radicular bone resulted in a socket with a low-level residual septum.

Cone-beam computed tomography (CBCT) scanning and the use of implant planning software revealed a narrow ridge despite the presence of the mandibular permanent lateral incisors. The decision

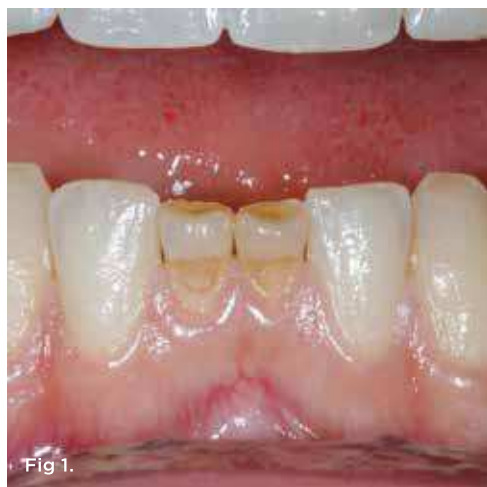

Fig 1.

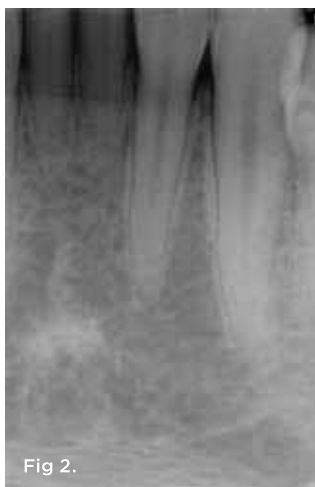

Fig 2.

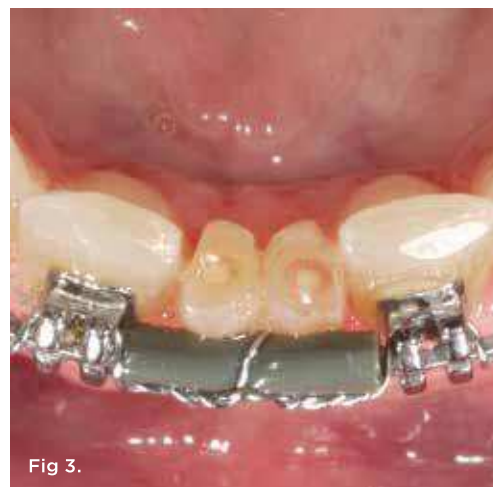

Fig 3.

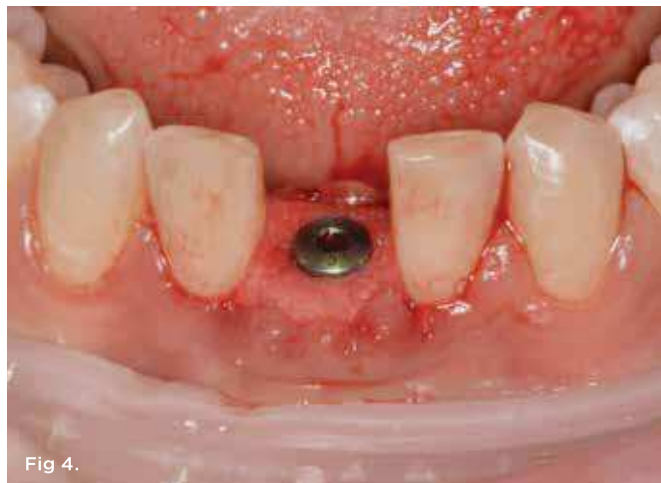

Fig 4.

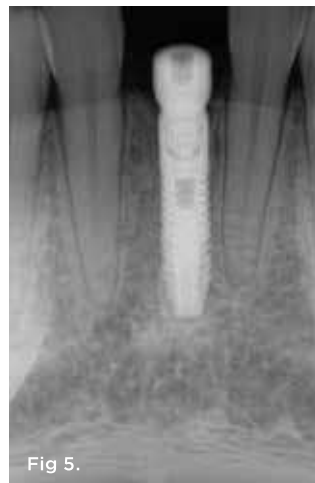

Fig 5.

**Fig 1.** Primary teeth with no permanent incisor replacements. The space would be too wide to replace both primary teeth with a single restoration and too narrow to accommodate two implants. **Fig 2.** Initial radiograph showing congenitally missing permanent lower incisors. **Fig 3.** Incisal view showing interproximal stripping of incisors to be extracted (orthodontic treatment by Yan Razdolsky, DDS). **Fig 4 and Fig 5.** Properly aligned implant (implant placement by periodontist David Barack, DDS).

to place a 3-mm x 13-mm implant was made to accommodate the restorative requirements of the planned restoration and preserve maximal facial bone thickness. The site was prepared in a usual manner to accommodate primary implant stability, and the implant was placed with an emphasis on protecting the facial and lingual plates.

A slow-acting deproteinized bovine bone mineral (DBBM) xenograft bone particulate (Bio-Oss®, Geistlich, geistlich-na.com) graft was placed into the residual socket space to minimize volumetric contraction of the alveolar ridge. Decortication of the facial plate was performed and additional DBBM was placed outside the facial plate to further augment the hard tissue. A 1.7-mm thick sheet of acellular dermal matrix (Symbios Perioderm, Dentsply Sirona) was prepared by hydrating the graft in a tetracycline/sterile saline solution and then punching it to fit around a healing abutment. The acellular dermal matrix was placed over the facial, crestal, and lingual surfaces to contain the DBBM graft and augment gingival thickness. The flaps were sutured into place using 5-0 vicryl interrupted sutures with slight exposure of the graft along the proximal aspects of the healing abutment.

The authors prefer to plan for screw-retained crowns even though some situations may call for a crown design that might

require cementation. A custom CAD/CAM abutment (Atlantis®, Dentsply Sirona) was designed to provide ideal soft-tissue support and depth and to create a proper abutment configuration for the final crown. Even with a properly placed implant, the incisal third should not interfere with the screw-access position so that there may be sufficient incisal width and metal support for the porcelain and final crown. When screw access interferes with this concept, the angle screw-access technique is an excellent option that allows for a crown to be cemented onto the abutment while a new path (usually more lingual) is established for affixing the crown-abutment complex to the implant.<sup>11</sup>

The presence of submucosal cement has been related to peri-implant mucositis and bone loss.<sup>12</sup> The benefits of using a screw-retained crown versus a cemented crown—particularly retrievability and the lack of the need for cement removal—have been extensively described in the literature.<sup>13</sup> Despite the best efforts of clinicians to minimize the presence of submucosal cement, residual cement may not be detected clinically or radiographically.<sup>14</sup> The literature presents inconclusive assessment of a thin versus a thick biotype in regard to long-term maintenance. Although clinically a thick, dense, keratinized tissue surrounding implants

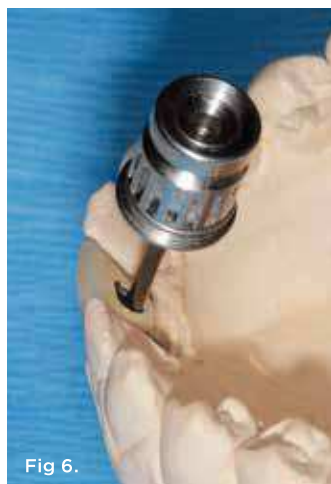

Fig 6.

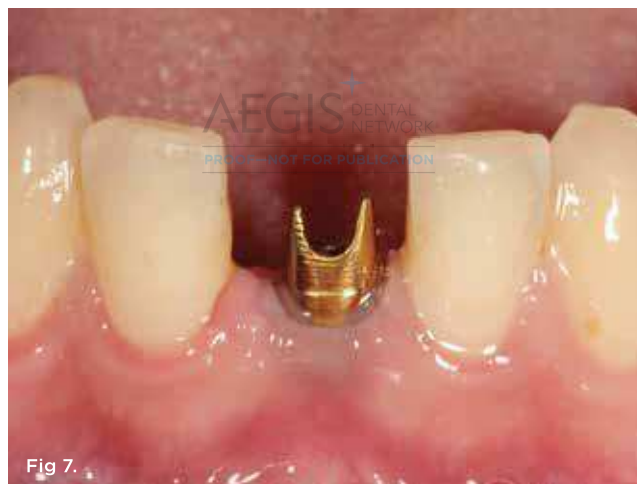

Fig 7.

**Fig 6.** Angle screw access allows for up to 30-degree angulation correction utilizing a special round head screw and driver. **Fig 7.** Abutment was tried in the mouth for verification. **Fig 8.** Crown was seated on the CAD/CAM abutment on a stone model with screw-access hole covered prior to final cementation. **Fig 9.** Final screw-retained crown (laboratory work by Toshiyuki Fujiki, RDT).

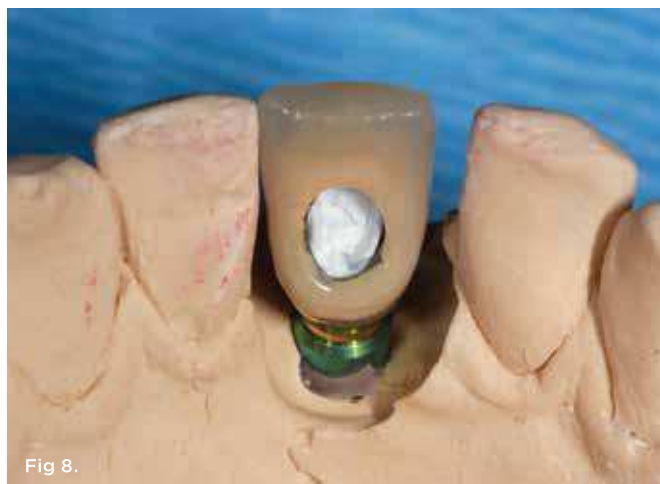

Fig 8.

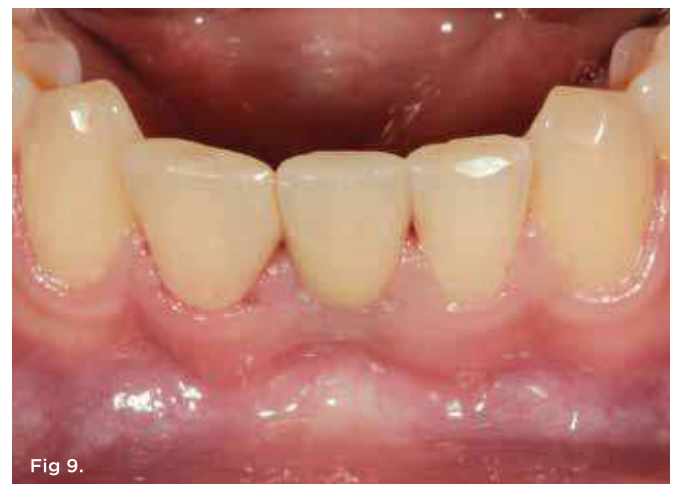

Fig 9.

is preferred, factors influencing soft-tissue maintenance include but are not limited to proper oral hygiene, implant type and design, abutment materials utilized (eg, gold, titanium, zirconia), and abutment surface decontamination. Longer follow-up evaluation is needed, as the shift from mucositis to peri-implantitis requires the detection of early signs of bone loss, which demands a longitudinal evaluation.<sup>15</sup>

Angle screw access allows for up to 30-degree angulation correction using a specially designed round head screw and driver (Figure 6).<sup>16,17</sup> The crown is cemented in the laboratory and, as was done in this case, the crown-abutment configuration is screw-retained and delivered in the mouth as one piece. The abutment was tried in the mouth to verify that the computer design matched the original plan prior to cementation of the crown onto the CAD/CAM abutment extraorally (Figure 7). The crown was then seated on the CAD/CAM abutment on a stone model, and the screw-access hole was covered with Teflon™ tape before final cementation with permanent cement (Figure 8).

Lower incisors are narrow in the mesial-distal direction at the incisal area, and even narrower still at the gingival area, and therefore can present anatomical challenges. Because orthodontic treatment in this case was shortened due to personal needs and desires of the patient as previously mentioned, the possible need for bonding adjacent to each incisor to improve esthetics was discussed with the patient; ultimately, however, bonding was required only on one site. Figure 9 shows the final restoration delivered as a screw-retained crown with slight gingival-mesial bonding on the adjacent lateral incisor to balance mesial-distal shape for the lower incisors.

To reiterate, this patient's goal was to improve cosmetics. The intent was not to expand arches or to create space for two implants, which would have involved significantly more complex treatment. Besides orthodontics, there would have been a potential need for bone grafting on both upper and lower arches, adding considerable time, expense, and maintenance to the treatment, while lowering predictability. The patient was never interested in such treatment. Moreover, she had a stable posterior bite with no problems with occlusion. This treatment successfully addressed her esthetic concerns, caused no compromise to existing teeth or supporting bone, and provided a solution that was far more easier to manage than changing occlusion and canine guidance.

## Case 2

Though not as common an occurrence in dentistry as congenitally missing teeth, patients do occasionally present missing maxillary canines and lateral incisors bilaterally.<sup>18</sup> In this case, a 24-year-old female patient presented with this situation. She had undergone orthodontic treatment twice and yet was still left with an esthetic shortcoming. Achieving an esthetic outcome with acceptable proportions was complicated because of displayed worn incisal edges due to the patient's parafunctional habits. Four upper congenitally missing anterior teeth were noticed at an early age, and orthodontic treatment was able to provide a stable occlusion; however, the resulting cosmetic mesial-distal space available for these missing teeth was deficient and inadequate for replacement of all four teeth.

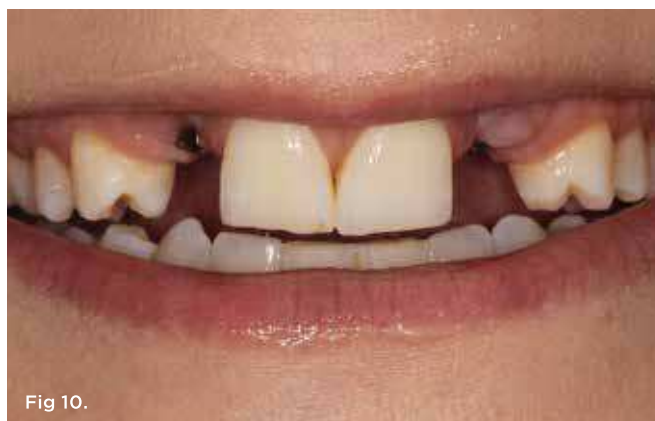

Fig 10.

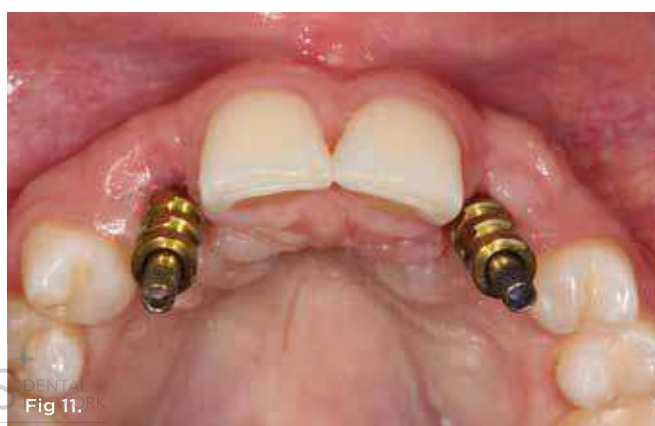

Fig 11.

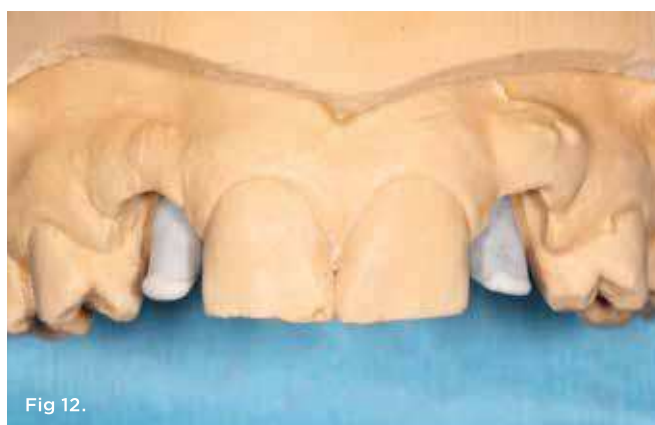


Fig 12.

**Fig 10.** Implants were placed to replace missing upper lateral incisors. Cosmetic-prosthetic management was clearly a concern with the patient's smile (surgical management by oral surgeon Leslie A. David, DDS). **Fig 11.** Implant placement was ideal for delivering a final screw-retained restoration. **Fig 12.** Masked provisional titanium cylinders.

Oftentimes, though the dental team, including all the various disciplines involved, may prefer to provide what it believes to be an ideal treatment, the actual treatment must fit the patient's needs and desires at the time. The best treatment option for the patient must be considered, provided no long-term compromise is anticipated or an irreversible condition that may be subject to failure is implemented.

While a CBCT scan was not available for this patient, the communication between the oral surgeon and prosthodontist addressed surgical limitations for desired implant size and placement, taking into account the patient's thin buccal-lingual ridge width. The most critical prosthetic desire was for screw access to be near the cingulum area. If it was possible, an implant diameter of at least 3.5 mm to 4 mm would have been ideal; unfortunately, however, such a diameter would have compromised buccal-palatal bone width. Therefore, 3-mm-diameter implants (OsseoSpeed EV) were placed (Figure 10). Preservation of a thick keratinized mucosa also was maintained through meticulous surgical management.

The evolution of dental implants has included the development of anatomically specific healing screws for insertion after the implant has been placed (Figure 11). Nevertheless, often, the emergence through the soft-tissue profile may still need to be customized with a provisional restoration. This is essential in terms of supporting facial/lingual and proximal soft tissues.<sup>19</sup> Allowing sufficient time for tissue maturation is critical,<sup>20</sup> and such time may vary for each individual situation (Figure 12 through Figure 14). Often a flat-to-concave emergence profile is recommended for the abutment-crown to maintain as much tissue volume as possible, especially in

cosmetic areas.<sup>21</sup> In this particular situation, the contour needed to be convex for proper tissue support.

Figure 15 shows the physiologically sculpted soft tissue created by the provisional restoration. Maturation and stability was achieved prior to final impressioning.

An open-tray impression coping was then surrounded at the apex with painted-on modeling resin (Pattern Resin™, GC America, gcamerica.com) to support the soft-tissue contours created by the temporary restoration (Figure 16). CAD/CAM abutments (Atlantis) and crowns were then designed to support the molded tissue (Figure 17 and Figure 18). As shown in Figure 19, crowns were seated on the custom abutments with a lingual screw access, enabling permanent cementation to take place outside the mouth. The final crowns were seated on the abutments extraorally (Figure 20). The final restorations along with bonding on the premolars to close diastemas are shown in Figure 21. Final radiographs (Figure 22 and Figure 23) demonstrate excellent fit and transition among the implants, abutments, and final crowns.

### Discussion

Esthetic outcomes with implant therapy depend on many different variables. While proximal soft-tissue papillae are mainly

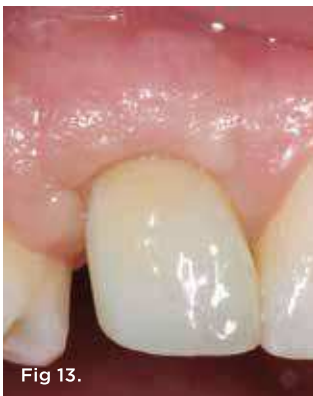

Fig 13.

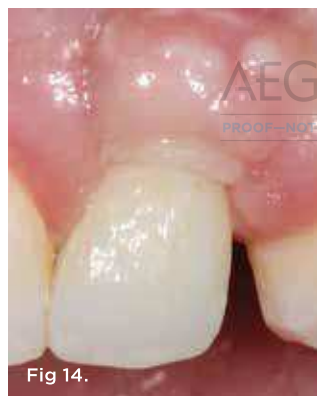

Fig 14.

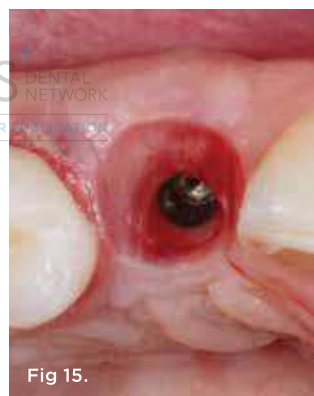

Fig 15.

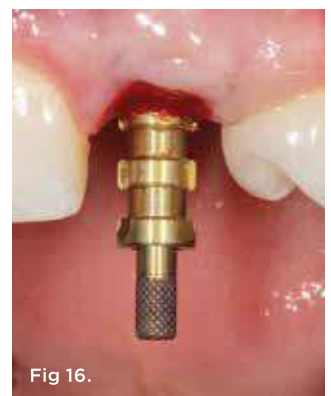

Fig 16.

**Fig 13 and Fig 14.** Provisional restorations (Fig 13, right lateral view; Fig 14, left lateral view) for evaluation of esthetics and soft-tissue development prior to taking final impressions. **Fig 15.** Physiologically sculpted soft tissue created by the provisional restoration at No. 7. **Fig 16.** Open-tray impression coping with modeling resin, No. 10. **Fig 17 and Fig 18.** CAD/CAM abutment (Fig 17) and crown (Fig 18) designed to support molded tissue, No. 10. **Fig 19.** Crowns seated on custom abutments with lingual screw access.

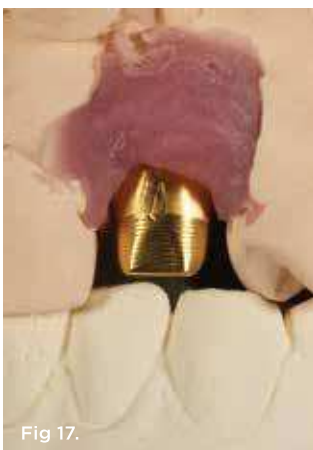

Fig 17.



Fig 18.

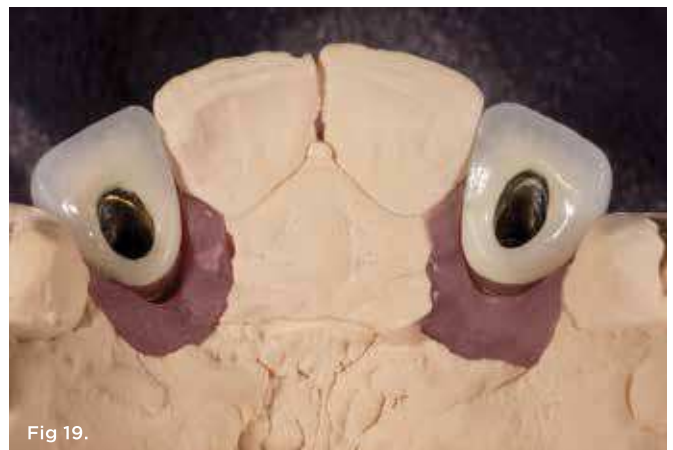
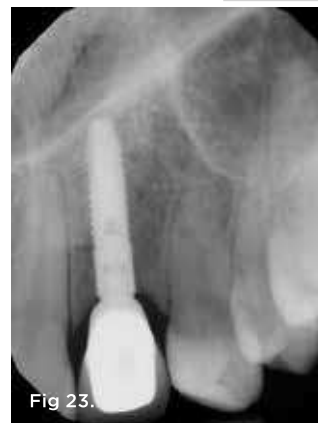
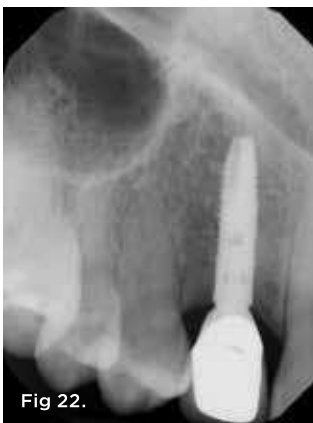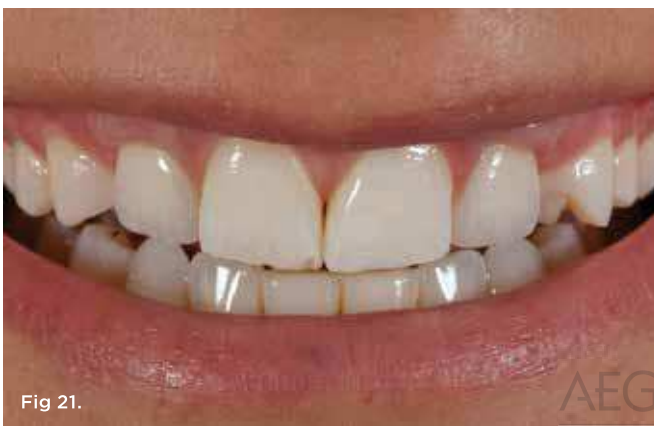Fig 19.



**Fig 20.** Final crowns were cemented on abutments extraorally. **Fig 21.** Patient's smile with final restoration and bonding on the premolars closing diastemas (laboratory work by Toshiyuki Fujiki, RDT). **Fig 22 and Fig 23.** Final radiographs showing excellent transition and fit among implant, abutment, and crown (implant placement by Leslie A. David, DDS).



supported by the presence of an intact periodontium around the adjacent natural teeth,<sup>22</sup> contours of the submucosal abutment/crown play a critical role as well. Gingival recession may be found more frequently in patients demonstrating a thin periodontal phenotype.<sup>23</sup> Even when ideal conditions regarding hard- and soft-tissue dimensions exist and thick periodontal phenotype is present, mesial-distal spaces available for implant-supported restorations will still have specific requirements. In clinical situations such as congenitally missing teeth, occlusally based treatment planning in orthodontics often results in spacing that is less than ideal when patients present for esthetic therapy. Therefore, it is crucial to diagnose congenitally missing teeth at an early age and plan for

replacement of these missing teeth with implants once skeletal maturity is completed.

#### ABOUT THE AUTHORS

##### **Sergio Rubinstein, DDS**

*Private Practice specializing in Prosthodontics, Cosmetic Dentistry, and Implant Dentistry, Skokie, Illinois*

##### **Barry P. Levin, DMD**

*Clinical Associate Professor, Department of Graduate Periodontology, University of Pennsylvania, Philadelphia, Pennsylvania; Diplomate, American Board of Periodontology; Private Practice, Jenkintown, Pennsylvania*

##### **Alexandra Fulreader, DDS**

*Private Practice, Chicago, Illinois*

##### **David Barack, DDS**

*Diplomate, American Board of Periodontology; Private Practice specializing in Periodontics and Implant Dentistry, Skokie, Illinois*

##### **Toshiyuki Fujiki, RDT**

*Master Laboratory Technician, Dental Reconstruction Center, Skokie, Illinois*

#### REFERENCES

1. American Association of Orthodontists. AAO website. [https://www.aaoinfo.org/\\_/frequently-asked-questions/](https://www.aaoinfo.org/_/frequently-asked-questions/). Accessed April 25, 2019.
2. Rouse JS. Sleep prosthodontics: a new vision for dentistry. *Inside Dentistry*. 2013;9(7):60-78.
3. Salama H, Salama MA, Garber D, Adar P. The interproximal height of bone: a guidepost to predictable aesthetic strategies and soft tissue contours in anterior tooth replacement. *Pract Periodontics Aesthet Dent*. 1998;10(9):1131-1141.
4. Rubinstein S, Salama M, Garber D, Salama H. The reverse pathway: parameters for the integration of functional aesthetics with implants. *J Implant Adv Clinical Dent*. 2010;2(4):19-29.
5. Buser D, Chappuis V, Bornstein MM, et al. Long-term stability of contour augmentation with early implant placement following single tooth extraction in the esthetic zone: a prospective, cross-sectional study in 41 patients with a 5- to 9-year follow-up. *J Periodontol*. 2013;84(11):1517-1527.
6. Spray JR, Black CG, Morris HF, Ochi S. The influence of bone thickness on facial marginal bone response: stage 1 placement through stage 2 uncovering. *Ann Periodontol*. 2005;5(1):119-128.
7. Levin BP, Chu SJ. Changes in peri-implant soft tissue thickness with bone grafting and dermis allograft: a case series of 15 consecutive patients. *Int J Periodontics Restorative Dent*. 2018;38(5):719-727.
8. Le BT, Borzabadi-Farahani A, Pluemsakunthai W. Is buccal angulation of maxillary anterior implants associated with the crestal labial soft tissue thickness? *Int J Oral Maxillofac Surg*. 2014;43(7):874-878.
9. Linkevicius T, Apse P, Grybauskas S, Puisys A. Influence of thin mucosal tissues on crestal bone stability around implants with platform switching: a 1-year pilot study. *J Oral Maxillofac Surg*. 2010;68(9):2272-2277.
10. Livas C, Jongsma AC, Ren Y. Enamel reduction techniques in orthodontics: a literature review. *Open Dent J*. 2013;7:146-151.
11. Gjølvd B, Sohrabi MM, Chrcanovic BR. Angled screw channel: an alternative to cemented single-implant restorations—three clinical examples. *Int J Prosthodont*. 2016;29(1):74-76.
12. Wilson TG Jr. The positive relationship between excess cement and peri-implant disease: a prospective clinical endoscopic study. *J Periodontol*. 2009;80(9):1388-1392.
13. Linkevicius T, Vindasiute E, Puisys A, Peculiene V. The influence for margin location on the amount of undetected cement excess after delivery of cement-retained implant restorations. *Clin Oral Implants Res*. 2011;22(12):1379-1384.
14. Pette GA, Ganeles J, Norkin FJ. Radiographic appearance of commonly used cements in implant dentistry. *Int J Periodontics Restorative*

*Dent.* 2013;33(1):61-68.

**15.** Sanz-Martín I, Sanz-Sánchez I, Carrillo de Albornoz A, et al. Effects of modified abutment characteristics on peri-implant soft tissue health: a systematic review and meta-analysis. *Clin Oral Implants Res.* 2018;29(1):118-129.

**16.** Farré-Berga O, Cercadillo-Ibarguren I, Sánchez-Torres A, et al. Novel ball head screw and screwdriver design for implant-supported prostheses with angled channels: a finite element analysis. *J Oral Implantol.* 2018;44(6):416-422.

**17.** Berroeta E, Zabalegui I, Donovan T, Chee W. Dynamic abutment: a method of redirecting screw access for implant-supported restorations: technical details and a clinical report. *J Prosthet Dent.* 2015;113(6):516-519.

**18.** Rakhshan V. Congenitally missing teeth (hypodontia): a review of the literature concerning the etiology, prevalence, risk factors, patterns and treatment. *Dent Res J (Isfahan).* 2015;12(1):1-13.

**19.** Su H, Gonzalez-Martin O, Weisgold A, Lee E. Considerations of implant abutment and crown contour: critical contour and subcritical contour. *Int J Periodontics Restorative Dent.* 2010;30(4):335-343.

**20.** Small PN, Tarnow DP. Gingival recession around implants: a 1-year longitudinal prospective study. *Int J Oral Maxillofac Implants.* 2000;15(4):527-532.

**21.** Rompen E, Raepsaet N, Domken, et al. Soft tissue stability at the facial aspect of gingivally converging abutments in the esthetic zone: a pilot clinical study. *J Prosthet Dent.* 2007;97(6 suppl):S119-S125.

**22.** Nisapakultorn K, Suphanantachai S, Silkosessak O, Rattanamongkolgul S. Factors affecting soft tissue level around anterior maxillary single-tooth implants. *Clin Oral Implants Res.* 2010;21(6):662-670.

**23.** Kan JY, Rungcharassaeng K, Umezu K, Kois JC. Dimensions of peri-implant mucosa: an evaluation of maxillary anterior single implants in humans. *J Periodontol.* 2003;74(4):557-562.